

## Yes, we can: reliable colonic closure with the Padlock-G clip in a survival porcine study (with video)

Carlos Guarner-Argente, MD, Henry Córdova, MD, Graciela Martínez-Pallí, MD PhD, Ricard Navarro, MD, Miriam Cuatrecasas, MD PhD, Cristina Rodríguez de Miguel, Mireia Beltrán, Antonio M. Lacy, MD PhD, Angels Ginès, MD PhD, Maria Pellisé, MD PhD, Josep Llach, MD PhD, Glòria Fernández-Esparrach, MD PhD

Barcelona, Spain

**Background:** Secure closure of the colonic access site is one of the most important issues for the development of natural orifice transluminal endoscopic surgery.

**Objective:** To evaluate the feasibility, reproducibility, and efficacy of a new over-the-scope clip.

**Design:** Descriptive study, in vivo porcine colon.

**Intervention:** In 10 female Yorkshire pigs weighing 30 to 35 kg, a 10-mm colotomy was performed by using a needle-knife and advancing the endoscope to the peritoneal cavity. Colonic closure was performed by using the Padlock-G clip (Aponos Medical, Kingston, NH) delivered with the Lock-It system (Aponos).

**Main Outcome Measurements:** Animals were monitored daily for signs of peritonitis and sepsis over a period of 14 days. During necropsy, the peritoneal cavity was examined, and the colon segment containing the incision was excised for pathological study.

**Results:** Closure was achieved in all cases. Nine of 10 pigs survived 14 days without complications, but 1 pig was killed immediately after the procedure because of severe bleeding during the colonic incision. The median closure time was 8 minutes (range 1-30 minutes). At necropsy, adhesions were observed in 5 cases. The incision was hardly visible at the serosa side in 3 cases and was not identified in 6 cases. In 6 cases, the clip was still slightly attached to the mucosa, and it was not found in 3 cases. The pathological study revealed a complete remodeling of the colonic wall in all cases.

**Limitations:** Animal model, noncomparative study.

**Conclusion:** The Padlock-G clip procedure is feasible, reproducible, effective, and easy to perform, and it provides a reliable colonic closure.

DISCLOSURE: G.F.-E. had a grant P108/90026 from the Instituto de Salud Carlos III. G.F.-E. thanks the Generalitat de Catalunya (AGAUR, BE-100022) and the Societat Catalana de Digestologia for supporting her training in NOTES. The authors would like to thank Olympus Medical Europe (Hamburg, Germany) for providing with the equipment free of charge for this study. No other financial relationships relevant to this publication were disclosed.

Copyright © 2010 by the American Society for Gastrointestinal Endoscopy  
0016-5107/\$36.00

doi:10.1016/j.gie.2010.06.054

Received May 12, 2010. Accepted June 14, 2010.

Current affiliations: Endoscopy Unit (C.G.-A., H.C., C.R.d.M., M.B., A.G., M.P., J.L., G.F.-E.), Anesthesiology Department (G.M.-P., R.N.), Pathology Department, CDB (M.C.), Surgical Department (A.M.L.), Hospital Clinic, University of Barcelona, IDIBAPS, CIBEREHD, Barcelona, Spain.

Reprint requests: Glòria Fernández-Esparrach, MD, PhD, Endoscopy Unit, Gastroenterology Department, Hospital Clinic, Villarroel 170, 08036 Barcelona, Spain.

Natural orifice transluminal endoscopic surgery holds great appeal as a less-invasive alternative to laparoscopic surgery. As natural orifice transluminal endoscopic surgery heads toward human trials, it is crucial to have a safe, fast, and reproducible method that allows the performance and closure of transluminal incisions.<sup>1-3</sup> The colon is a potential gateway that can be used in the general population, and its use as a portal may allow better vision and mobility in the upper abdominal cavity. Several closure techniques have been tested in the colon, including clips<sup>4-9</sup> and T-tags<sup>10</sup> as well as more complex suturing devices.<sup>11</sup> However, most of these devices are time-consuming and often are difficult to implement endoscopically. Current data do not allow definitive conclusions regarding the different options for this indication.

The aim of this study was to evaluate the feasibility, reproducibility, and efficacy of the Padlock-G clip (Aponos Medical, Kingston, NH) for colonic closure in a survival porcine model.

**Figure 1.** Padlock-G clip. Once deployed, the nitinol clip (which is deformed to fit the cap) recovers its habitual shape, approaching and tightening the grasped tissues.

## MATERIALS AND METHODS

### Animals

Ten female Yorkshire pigs weighing 30 to 35 kg were included in the study. All procedures were performed with pigs under general anesthesia with endotracheal intubation and mechanical ventilation.

The study was conducted at the University of Barcelona Medical School's animal facilities. The protocol was approved by the University of Barcelona's Animal Ethics Committee.

### The Padlock-G clip

The Padlock-G clip is a hexagonal nitinol ring with 6 inner needles (Fig. 1), and it is delivered by the Lock-It delivery system (Aponos) (Fig. 2).

### Procedure

All colons were prepared with water enemas until clear visualization with a nonsterile endoscope (GIF 160; Olympus Medical Systems, Europe, Hamburg, Germany). Afterward, an iodated solution followed by ceftriaxone suspension was instilled. From this point on, all the instruments used were sterile or high-level disinfected. With a regular endoscope, a 10-mm incision was made at 15 to 20 cm of the anal verge with a needle-knife; afterward, and using the needle-knife as a guide-wire the scope was advanced into the abdominal cavity.

The scope was retrieved, and the deployment cap with the Padlock-G clip was placed at the tip. The incision was identified, and the margins were introduced inside the cap

### Take-home Message

- Secure closure of the access site is one of the most important issues for the development of natural orifice transluminal endoscopic surgery. However, most new devices are time-consuming and often difficult to implement endoscopically. The Padlock-G clip (Aponos Medical, Kingston, NH) is an over-the-scope clip, and because of its simplicity and efficacy, the authors believe it might be a good solution for both iatrogenic and intentional perforations of the colon wall. Further studies are warranted to confirm our results and to evaluate long-term complications before expanding use of the procedure to humans.

with graspers or suction. The nitinol ring was immediately released pushing the handle, forming a pseudopolyp that included the incision (Video 1, available online at [www.giejournal.org](http://www.giejournal.org)) (Fig. 3).

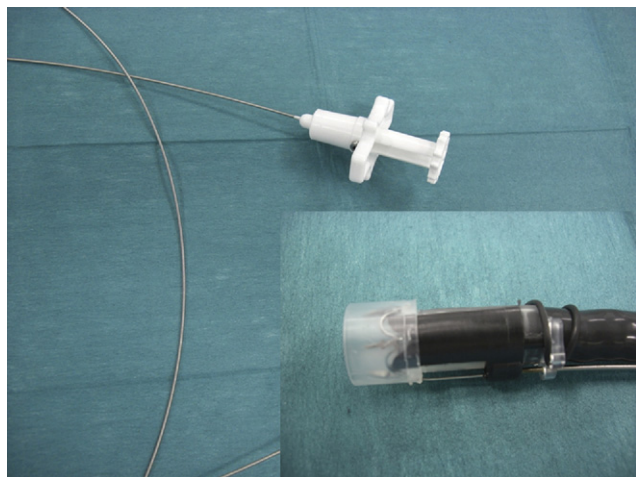
The tightness of the closure was confirmed by means of air insufflation and the ability to maintain colonic distension with stable peritoneal pressure.

### Postoperative care and necropsy

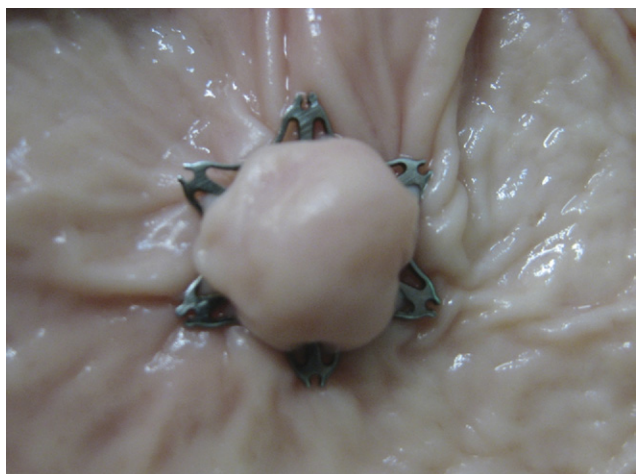
All animals received intravenous ceftriaxone, 1 g daily during 3 days, and were monitored daily for signs of sepsis during the next 14 days. During necropsy, the peritoneal cavity was examined for signs of peritonitis or other complications. The colonic access segment was examined and excised for pathological study.

## RESULTS

The complete cleansing of the pigs' colons was difficult with the presence of fecal content. In two cases, the clip was blocked inside the delivering system, and we had to use a second one, so we used 12 clips for 10 closures. In 2 of 3 initial cases in which the incision was pulled with graspers, one standard endoclip was placed as an adjunctive closure method. The median time for closure, including the identification of the incision site, was 8.5 minutes (range 1-30 minutes). Nine of 10 animals survived for 2 weeks without apparent complications, whereas one had to be killed immediately after the procedure because of severe bleeding during the incision. At necropsy, adhesions were found in 5 cases, but no signs of peritonitis or bleeding were observed in any case. The ring was still slightly attached to the mucosa in 6 cases. There were no macroscopic ulcerations at the implantation site in any case. The pathologic study revealed a complete rebuilding of the colonic wall in all cases (Fig. 4). We identified two main patterns according to fibrosis or inflammation predominance. The fibrotic group ( $n = 5$ ) showed an almost complete architectural restoration of the colonic wall with increased wall thickness related to an enlarged width of



**Figure 2.** The Lock-It delivery system (Aponos Medical, Kingston, NH) consists of a transparent application cap that is located at the tip of the endoscope and a trigger cable parallel to the scope that connects to a handle, which delivers the clip with a push maneuver.



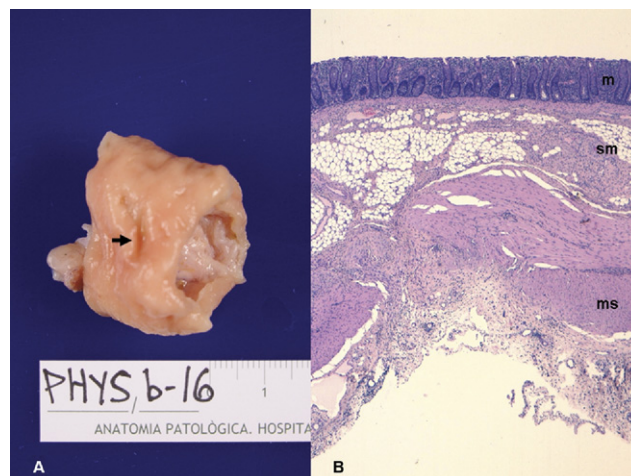
**Figure 3.** Endoscopic view of a Padlock-G clip (Aponos Medical, Kingston, NH) deployed: a pseudopolyp is created that contains the incision in the center.

the muscularis propria. The inflammatory group ( $n = 4$ ) showed mucosal ulceration with granulation tissue, microabscesses, and foreign-body granulomas with abundant food material in all the wall layers and a total disruption of the muscularis propria.

## DISCUSSION

In this pilot study, we present our results with the use of the Padlock-G clip for colotomy closure, and we demonstrate its effectiveness for a secure closure.

The use of this device already has been reported in explanted and in vivo porcine stomachs,<sup>12,13</sup> but this is the first description of its use for colonic closure. The design of the delivery system has been improved, and the current



**Figure 4.** **A,** A macroscopic view of the incision (*arrow*) at the serosa side. **B,** The microscopic view shows complete healing of the mucosa (*m*) and submucosa (*sm*) layers, whereas the muscularis propria (*ms*) shows architectural distortion with fibrosis substitution and chronic inflammation (H&E, orig. mag.  $\times 20$ ).

transparent application cap allows better visualization than did the former metallic pod. Another considerable difference as compared with previous reports is that we do not use T-tags before the application of the clip, which translates into a significant reduction of procedure time.

Another over-the-scope clip system has been evaluated in the porcine model,<sup>8,9,14-16</sup> and it already has been used in clinical practice for the treatment of GI bleeding and colonic perforations.<sup>17,18</sup> The Padlock-G clip has some attributes that are advantageous. First, the delivery system is located parallel to the endoscope, it does not use the working channel, and its handle is not attached to the endoscope handle, allowing more maneuverability. Second, the hexagonal shape of the nitinol ring might reduce the risk of mucosal trauma associated with other systems. Prospective trials comparing these devices are needed in order to evaluate these potential advantages.

Little is known about the early healing stages of trans-visceral access sites. In the majority of studies, healing of the gastric or colonic access site was assessed only by visual inspection of the serosal surface.<sup>11</sup> In our study, we assessed macroscopic and microscopic healing of colonic access sites at day 14. We found that all incisions were effectively closed and healed at macroscopic inspection with no spillage into the peritoneal cavity. Moreover, the pathological study revealed a complete reconstruction of the colonic wall in all cases. Most of the incisions had imperceptible macroscopic lesions and very subtle histologic fibrous changes. Some inflammatory cases had architectural alterations, but no transmural necrosis or perforation was seen in any case. These results are very different from those described with use of an endoloop, another endoscopic method for closure. With an endoloop, animals showed substantial granulation tissue fill,

with fibrin deposition bridging the tissue defect and transmural ulcerations on day 7.<sup>19</sup> The absence of ulcerations in most cases with the Padlock-G clip reflects adequate tissue perfusion with minimal wound tension.

The method used for introducing the incision inside the cap was suction in 7 cases, and although we were very concerned about the possibility of catching adjacent organs into the closure, we did not find this complication in any of the cases.

The present study has some limitations. First, we did not include a control group in which conventional clipping techniques were used. Second, the use of an animal model cannot completely simulate how the device would act in the human colon. Third, the study size is small, but because it was not a comparative study, we did not attempt to power it statistically.

In conclusion, the use of the Padlock-G clip for colonic closure in a porcine model is easy, fast, effective, and reproducible. We believe this novel endoscopic device might be a reliable treatment for either intentional colonic incision or iatrogenic perforations of the colon wall. Further studies are warranted to confirm our results before the procedure is expanded to use in humans.

## REFERENCES

1. Kallou AN, Singh VK, Jagannath SB, et al. Flexible transgastric peritoneoscopy: a novel approach to diagnostic and therapeutic interventions in the peritoneal cavity. *Gastrointest Endosc* 2004;60:114-7.
2. Kantsevov SV, Jagannath SB, Niiyama H, et al. Endoscopic gastrojejunostomy with survival in a porcine model. *Gastrointest Endosc* 2005;62:287-92.
3. ASGE/SAGES Working Group on Natural Orifice Transluminal Endoscopic Surgery White Paper October 2005. *Gastrointest Endosc* 2006;63:199-203.
4. Devereaux CE, Binmoeller KF. Endoclip: closing the surgical gap. *Gastrointest Endosc* 1999;50:440-2.
5. Raju GS, Ahmed I, Shibukawa G, et al. Endoluminal clip closure of a circular full-thickness colon resection in a porcine model (with videos). *Gastrointest Endosc* 2007;65:503-9.
6. Raju GS, Ahmed I, Xiao SY, et al. Controlled trial of immediate endoluminal closure of colon perforations in a porcine model by use of a novel clip device (with video). *Gastrointest Endosc* 2006;64:989-97.
7. Sporn E, Miedema BW, Bachman SL, et al. Endoscopic colotomy closure after full thickness excision: comparison of T fastener with multiclip applier. *Endoscopy* 2008;40:589-94.
8. Schurr MO, Arezzo A, Ho CN, et al. The OTSC clip for endoscopic organ closure in NOTES: device and technique. *Minim Invasive Ther Allied Technol* 2008;17:262-6.
9. von Renteln D, Schmidt A, Vassiliou MC, et al. Endoscopic closure of large colonic perforations using an over-the-scope clip: a randomized controlled porcine study. *Endoscopy* 2009;41:481-6.
10. Park PO, Bergström M, Rothstein R, et al. Endoscopic sutured closure of a gastric natural orifice transluminal endoscopic surgery access gastrotomy compared with open surgical closure in a porcine model: a randomized, multicenter controlled trial. *Endoscopy* 2010;42:311-7.
11. Pham BV, Raju GS, Ahmed I, et al. Immediate endoscopic closure of colon perforation by using a prototype endoscopic suturing device: feasibility and outcome in a porcine model (with video). *Gastrointest Endosc* 2006;64:113-9.
12. Romanelli JR, Desilets DJ, Earle DB. Natural orifice transluminal endoscopic surgery gastrotomy closure in porcine explants with the Padlock-G clip using the Lock-It system. *Endoscopy* 2010;42:306-10.
13. Desilets DJ, Romanelli JR, Surti VC, et al. The ties that bind: durable, transmural, purse-string-like gastrotomy closure using a novel device [abstract]. *Gastrointest Endosc* 2007;65:AB292.
14. von Renteln D, Rudolph HU, Schmidt A, et al. Endoscopic closure of duodenal perforations by using an over-the-scope clip: a randomized, controlled porcine study. *Gastrointest Endosc* 2010;71:131-8.
15. von Renteln D, Vassiliou MC, Rothstein RI. Randomized controlled trial comparing endoscopic clips and over-the-scope clips for closure of natural orifice transluminal endoscopic surgery gastrotomies. *Endoscopy* 2009;41:1056-61.
16. Voermans RP, van Berge Henegouwen MI, Bemelman WA, et al. Novel over-the-scope-clip system for gastrotomy closure in natural orifice transluminal endoscopic surgery (NOTES): an ex vivo comparison study. *Endoscopy* 2009;41:1052-5.
17. Kirschniak A, Kratt T, Stuker D, et al. A new endoscopic over-the-scope clip system for treatment of lesions and bleeding in the GI tract: first clinical experiences. *Gastrointest Endosc* 2007;66:162-6.
18. Repici A, Arezzo A, De Caro G, et al. Clinical experience with a new endoscopic over-the-scope clip system for use in the GI tract. *Dig Liver Dis* 2009;41:406-10.
19. Mathews JC, Chin MS, Fernández-Esparrach G, et al. Early healing of transcolonic and transgastric natural orifice transluminal endoscopic surgery access sites. *J Am Coll Surg* 2010;210:480-90.